

So You Want to Be a Tumor Surgeon?

Here are some words to the wise regarding the management of soft tissue masses.

By Bryan C. Markinson, D.P.M.

Due to recent lively discussions on *PM News* surrounding the topic of soft tissue masses, I wanted to use this installment of *Issues in Podiatric Dermatology* to introduce some ideas regarding recognized management and surgical protocols of these lesions. For the purposes of this discussion, the term "soft tissue mass" includes any and all lesions involving muscle, tendon, fascia, blood vessels, nerves, and fat, not including the skin.

Some nerve sheath tumors are malignant.

In a recent *PM News* posting, a podiatrist showed us a photo of a completely (assumed) excised surgical specimen (Figure 1).

After she stated that she had "anticipated a ganglionic cyst," she went on to say that "clearly this lesion is a neurilemmoma." She ended her description with "the lesion was well-encapsulated and had the same consistency as an intermetatarsal neuroma." I assumed that after her surgery, she closed the wound and sent the "neurilem-

oma" for confirmatory pathological diagnosis. I am hopeful that the tissue pathology confirmed her eyeball diagnosis.

Although she does not say whether her stated findings are post- or pre-biopsy results, she intimated that we as clinicians surely

can arrive at the diagnosis because it was well-encapsulated by sight and had the same consistency as an intermetatarsal neuroma (I assumed on palpation). Presumably all worked out well with this doctor's case. There are alternative ways to handle this that would markedly decrease the chances of a possible horrendous outcome, and eliminate luck as a variable.

Consider this: Some of these nerve sheath tumors are malignant. As such, the surgery, while performed deftly, makes it absolutely impossible to define or estimate clear margins of resection if indeed the malignancy was found to exist at the margins of resection. This would obligate a future surgeon charged with performing a wide local excision to do drastically

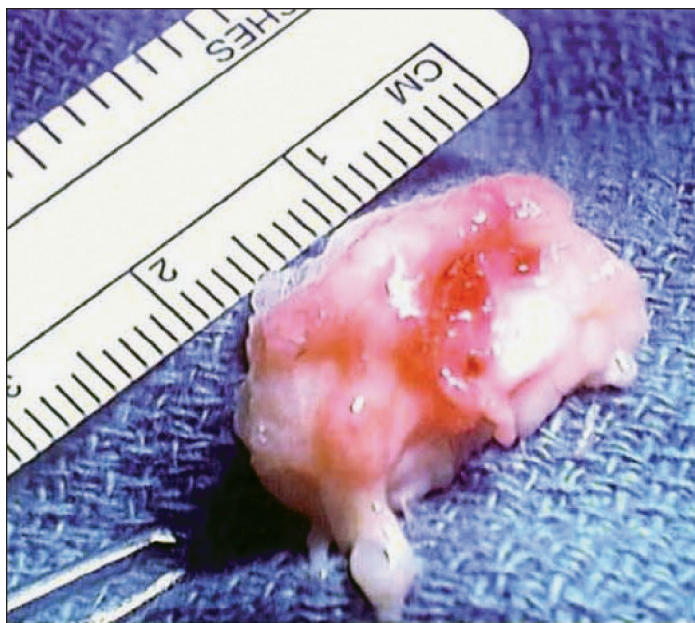


Figure 1: Neurilemmoma (as posted in *PM News*)

more surgery than otherwise would have been required if the original surgery were limited to an open incisional biopsy.

Additionally, it is along nerves that many malignancies spread locally. The observation that a lesion is well encapsulated does not always mean that it is. Often at histologic sectioning, this turns out not to be so.

In essence, there are cases of improperly worked up and inappropriately resected soft tissue masses that turn out to be malignancies. Musculoskeletal oncologists call these "unexpected or unintended malignancies," and when improperly or inappropriately resected, they may result in serious consequences for the patient.

Continued on page 212

Tumor Surgeon...

This is not only problematic for podiatrists, but also for general surgeons, vascular surgeons, and orthopedic surgeons, who have little or no training in musculoskeletal oncology, a distinct specialty, not an "area of interest."

Ten Suggestions

To avoid these instances of unexpected malignancy, or "I thought it was a ganglion," or "Aspiration yielded little fluid, so I injected it with cortisone," I recommend that everyone considering taking a scalpel to remove a soft tissue mass where any question exists as to the diagnosis consider the following: (These are purely risk management suggestions for better care of the patient and are not meant to apply any "standard.")

1) First and foremost—get a concurrent opinion as to your course of action. At a minimum, discuss the case with a musculoskeletal oncologist. You would be surprised as to what information can be forthcoming.

2) If any soft tissue mass you are looking at is 5 cm. in any dimension, be very suspicious. Do everything you can to establish the diagnosis, including referring the patient. Size can be determined best by ultrasound or MRI, or palpation, if clearly small or clearly large.

3) Try to determine if it is subcutaneous or intramuscular. This can be done by ultrasound or MRI. Subcutaneous malignancies tend to fare better. This is more applicable to deep thigh and buttock tumors.

4) Firmness is a bad sign. Sarcomas tend to be firm and painless until large.

5) Determine if the lesion is cystic or solid. Cancers tend to be solid, but there are high grade ma-

lignancies that can present largely as a cystic mass.

6) Masses that rapidly increase in size over a few months are more likely to be malignant than lesions that have enlarged slowly over many years. Pitfall: Occasionally, soft tissue sarcomas present with a history of many years duration.

7) Get a plain x-ray. Every soft tissue mass for which there will be intervention requires a plain x-ray. Evaluate for fat density (lipoma), calcifications (synovial sarcoma, hemangioma), ossification (osteosarcoma, myositis ossificans), and skeletal abnormalities (osteomyelitis, primary bone lesion, periosteal reaction from soft tissue tumor). MRI and CT provide additional information on extent, internal tumor characteristics, and whether the lesion is primarily bone or soft tissue.

8) Get an MRI with contrast. You need the contrast to avoid the nightmare of an unexpected vascular tumor. MRI and CT provide additional information on extent, internal tumor characteristics, and whether the lesion is primarily bone or soft tissue.

9) Do not do these procedures in the office. Virtually all literature supports that soft tissue mass management should be hospital-based. If you find yourself cutting into a mass in your office operator, you have robbed the patient of the ability to have a frozen section diagnosis, starting a cascade of trouble should the tumor you excise be malignant.

There are percutaneous biopsy procedures for soft tissue masses that can be done in-office, such as the Tru-

Cut needle biopsy, which delivers a spaghetti-shaped biopsy specimen from the tumor. If malignant, initial open surgery can be well planned for adequate resection at clear margins based on pre-operative imaging studies, and staging.

10) Plan an open incisional biopsy and get a frozen section in the OR. (Eyeball diagnosis and diagnosis based on palpation require a level of experience that most of us will never

achieve.) Sometimes, even the pathologist finds it tough to call whether or not they are looking at a malignancy or a benign lesion. If the lesion is benign, complete your resection. If it is malignant, close the wound. Then plan the wide local excision after the patient is adequately staged. In a hospital-centered environment, this should take a few days at most. ■

Recommended Reading

Surgery for Bone and Soft Tissue Tumors, Michael A. Simon, Dempsey S. Springfield, Editors, 1998 by Lippincott-Raven Publishers, Philadelphia, PA 19106.

Myhre-Jensen O: A consecutive 7-year series of 1331 benign soft tissue tumors. Acta Orthop Scand, 52:287-293, 1981.

Rydholm A, et al: Subcutaneous sarcoma: A Population-based study of 129 patients. J Bone Joint Surg, 73-B:662-667, 1991.

If any soft tissue mass you are looking at is 5 cm. in any dimension, be very suspicious.

Firmness is a bad sign.

Dr. Markinson is Chief of Podiatric Medicine and Surgery at The Leni and Peter W. May Department of Orthopedic Surgery, Mount Sinai School of Medicine, New



York City and Adjunct Professor, Division of Medical Sciences, New York College of Podiatric Medicine. He is a Trustee of the Council on Nail Disorders, an Affiliate of the American Academy of Dermatology.